

Case report

Open Access

## Stroke in inflammatory bowel disease: a report of two cases and review of the literature

Deepak Joshi\*, Tobias Dickel, Rakesh Aga and Gray Smith-Laing

Address: Department of Gastroenterology, Medway Maritime Hospital, Kent, UK

Email: Deepak Joshi\* - [djosh78@hotmail.com](mailto:djosh78@hotmail.com); Tobias Dickel - [tobias.dickel@hotmail.com](mailto:tobias.dickel@hotmail.com); Rakesh Aga - [rakesh.aga@medway.nhs.uk](mailto:rakesh.aga@medway.nhs.uk); Gray Smith-Laing - [gray.smith-laing@medway.nhs.uk](mailto:gray.smith-laing@medway.nhs.uk)

\* Corresponding author

Published: 21 March 2008

Received: 4 December 2007

*Thrombosis Journal* 2008, **6**:2 doi:10.1186/1477-9560-6-2

Accepted: 21 March 2008

This article is available from: <http://www.thrombosisjournal.com/content/6/1/2>

© 2008 Joshi et al; licensee BioMed Central Ltd.

This is an Open Access article distributed under the terms of the Creative Commons Attribution License (<http://creativecommons.org/licenses/by/2.0>), which permits unrestricted use, distribution, and reproduction in any medium, provided the original work is properly cited.

### Abstract

Thrombosis is a recognised complication of inflammatory bowel disease (IBD), in particular venous thrombosis. Arterial thrombosis, especially stroke is rare. There is a paucity of information regarding stroke in IBD and its management. The authors describe two cases of stroke in patients with IBD during periods of increased disease activity. The literature regarding this devastating complication and the procoagulant state that exists in IBD are reviewed.

### Background

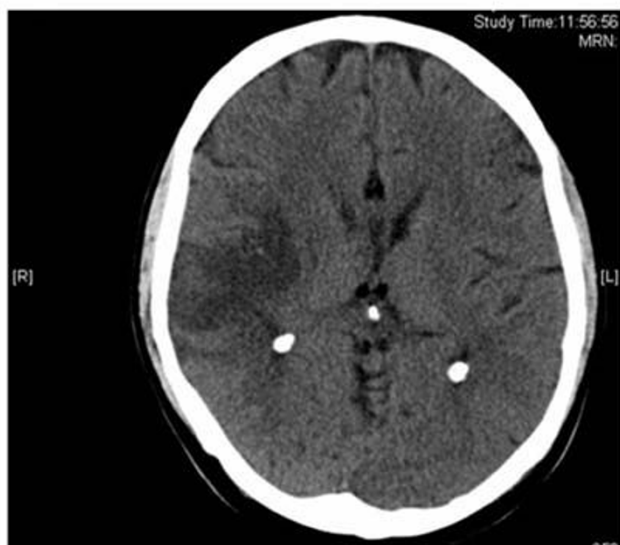
Thrombosis is a well-recognised complication of inflammatory bowel disease (IBD) and is an important cause of morbidity and mortality. The commonest are deep vein thrombosis and pulmonary emboli [1]. Arterial thrombosis, in particular stroke, is rare in IBD. No guidelines are available at present to help manage this severe complication. The authors describe two cases of stroke in patients with ulcerative colitis (UC).

#### Patient 1

A 55 year old, non-smoker, Caucasian man presented to the emergency room with left sided hemiparesis. The patient also had bloody diarrhoea (12 times a day). A diagnosis of ulcerative colitis had been made five years previously and the patient had been maintained on mesalazine only. The patient had been evaluated in the out-patient department three days earlier with an exacerbation of his UC and was started on prednisolone 40 mg daily only. There was no history of vascular disease. On examination the patient was normotensive (blood pressure 111/80 mmHg) and afebrile. Cardiovascular examination revealed normal heart sounds, and no carotid

bruits. Abdominal examination revealed tenderness in the left iliac fossa and reduced bowel sounds. A dense left sided hemiplegia was noted. Blood tests showed a raised white cell count of  $11.5 \times 10^9/L$  (NR 4–11) and C-reactive protein (CRP) of 29.6 mg/L (NR 0–5) and a thrombocytosis of  $566 \times 10^9/L$  (NR 150–400). Fasting cholesterol of 3.3 mmol/L (NR 1.3–5.2) and blood glucose of 3.3 mmol/L (NR 3.3–5.8) were both normal. Stool cultures were negative. An electrocardiogram demonstrated normal sinus rhythm. No evidence of cardiomegaly was noted on a chest radiograph. Trans-thoracic echocardiogram and carotid dopplers were normal. Computed tomography (Figure 1) of the brain confirmed an ischaemic infarct in the right parietal lobe.

Flexible sigmoidoscopy demonstrated an inflamed granular mucosa with loss of the vascular pattern to the proximal sigmoid colon. He was commenced on intravenous hydrocortisone (100 mg QDS) and subcutaneous low molecular weight heparin (LMWH). Total parenteral nutrition was also commenced because of the likelihood of poor enteral absorption. After 14 days of treatment with hydrocortisone he underwent a total colectomy



**Figure 1**  
**CT demonstrating large ischaemic infarct in the right parietal lobe.**

because of poor symptom control and worsening abdominal pain. Postoperative recovery was unremarkable. A thrombophilia screen (anti-thrombin, protein C and S, factor V Leiden) was negative. Twelve months post surgery the patient is mobilising independently with only mild weakness of the left upper limb.

#### **Patient 2**

A 24 year old Caucasian woman presented to the emergency room with a left sided headache, confusion and increased bowel frequency (8 times per day). UC had been diagnosed six months earlier at colonoscopy and subsequently treated with mesalazine 800 mg BD and prednisolone 10 mg OD. On examination the patient was afebrile and normotensive (BP 119/80 mmHg). A global aphasia was noted with no other neurological deficits. Blood tests revealed a raised white cell count of  $20.1 \times 10^9/L$  and CRP at 185 mg/L, and a thrombocytosis of  $641 \times 10^9/L$ . Trans thoracic echocardiogram and carotid dopplers were normal. CT of the brain demonstrated an ischaemic infarct of the left middle cerebral artery territory. A thrombophilia screen was negative. The patient was managed conservatively and made an uneventful recovery with no residual neurological deficit but subsequently developed epilepsy. Her colitis has remained well controlled with azathioprine.

#### **Discussion**

We describe two cases of stroke in patients with known UC. Neither patient had any risk factors for cerebrovascular disease. One patient required a subtotal colectomy for

failed medical treatment whilst the other patient made a full recovery and was spared surgery but developed epilepsy secondary to her stroke.

Deep vein thrombosis with or without pulmonary embolism remains the most common vascular event complicating inflammatory bowel disease. Thrombotic events involving the central nervous system are unusual. Cases of cerebral venous sinus thrombosis in IBD are well described [2,3]. Arterial thromboembolic complications occur less frequently [4] and the majority of cases seem to occur post surgery [5]. In a study of 7199 patients, only 7 patients with cerebrovascular disease were identified [6]. A review of the literature shows scattered case reports of arterial strokes in IBD [7-9]. Patients with ulcerative colitis appear to be more commonly affected than patients with Crohn's Disease [7]. Men and women are equally affected. Vitamin B6 deficiency leading to an acquired state of hyper-homocysteinaemia has also been described as a risk factor for stroke in IBD [7]. Active disease was also associated with the occurrence of stroke, but cases have been described during remission [4]. Pan-colonic disease has also been suggested as a risk factor for stroke. Significant morbidity is associated with arterial complications [10].

An increased risk of thrombosis is recognised in patients with IBD. The incidence of "thrombo-embolic (TE)" complications ranges between 1–8% [11]. The increased risk of TE complications appears to be unique to IBD when compared to other inflammatory conditions. Mieshler et al [12] demonstrated that IBD patients have a 3.6 fold higher risk of thromboembolism compared with controls. An increased risk was not seen in patients with coeliac disease or rheumatoid arthritis. The majority of TE cases (60%) in patients with IBD occurred during periods of increased disease activity or in the presence of gastrointestinal complications such as fistulae and abscesses [12].

All components of the coagulation cascade are thought to be involved in the pathogenesis of IBD [13]. This is the basis for the use of heparin as a treatment, and also accounts for the decreased incidence of IBD in patients with von Willenbrands disease and haemophilia [5]. A single cause for the hypercoagulable state that clearly exists in IBD has not been established. An increased frequency of Factor V Leiden, antithrombin deficiency and the prothrombin (G20210A) gene mutation have not been consistently identified [1]. Protein C and S levels have also been shown to be no different to controls [14]. Hyperhomocysteinaemia is associated with an increased risk of thrombosis. Homocysteine is generated via the metabolism of methionine and requires vitamins B6, B12 and folate. A point mutation (C677T) in the methylenetetrahydrofolate reductase (MTHFR) gene can lead to increased serum levels. An increased incidence of the point muta-

tion in the MTHFR in IBD patients with TE complications has not been established [1].

In the two cases described, both patients had evidence of active disease. Inflammation during episodes of increased disease activity is a potent prothrombotic stimulus due to fibrinolysis inhibition. Increased levels of pro-inflammatory cytokines (TNF and IL-6) and increased production of soluble CD40 ligand from activated platelets [15,16] are also thought to play an important role. Studies have also examined the role played by platelet-leukocyte aggregates (PLA) which are increased in patients with IBD, compared with healthy and inflammatory control subjects [17,18]. PLAs cause microinfarction and exacerbate thrombus formation by enhancing the production of tissue factor. Conventional risk factors for thrombosis such as immobility, dehydration, sepsis and surgery should not be forgotten.

Consequences of stroke in young patients can be devastating and even more complicated in the setting of active IBD. Conventional CT or magnetic resonance imaging should be performed to identify the anatomical distribution and the extent of the area affected. No guidelines are available for the treatment of stroke in IBD. The only evidence appears to be anecdotal, probably due to the paucity of cases. Treatment should involve the management of the underlying bowel disease and prevention or correction of acquired risk factors leading to the TE event. Novotny et al [10], proposed that all UC patients with an arterial TE event should undergo a colectomy due to the likelihood of pan-colonic disease and a poorer long term prognosis.

Prophylactic doses of LMWH are widely used in patients with IBD with increased disease activity, evidence of gastrointestinal complications, and during surgery or episodes of sepsis during hospital admissions. This is recommended by the British Society of Gastroenterology [19]. Anticoagulation, to prevent further thrombotic episodes, is a controversial because of the increased risk of intracerebral and GI bleeding, although patients have been successfully anticoagulated without bleeding complications [20]. Oral, colonic release, LMWH has now been used in the treatment of mild to moderate UC [21], and could represent a future therapeutic avenue. We suggest that all cases of stroke in IBD patients should be treated as in the general population with aspirin and modification of atherosclerotic risk factors. We do not advocate the need for total colectomy in the occurrence of an arterial TE event.

It is not uncommon for patients to present with de novo IBD with extra-intestinal manifestations which include vascular events. Clinical awareness of stroke as a compli-

cation of IBD is low. Guidelines are required to help guide physicians in the management of stroke in IBD. Investigations for thrombophilia should be reserved for those patients with atypical or recurrent thromboses or in those with a strong family history. Further research is needed to help establish the cause of the hypercoagulable state in IBD.

### Abbreviations

CT: Computed tomography; IBD: Inflammatory bowel disease; LMWH: Low molecular weight heparin; MTHFR: Methylene tetrahydrofolate reductase; PLA: Platelet-leukocyte aggregates; TE: Thrombo-embolic; UC: Ulcerative colitis.

### Competing interests

The author(s) declare that they have no competing interests.

### Acknowledgements

Dr AF Muller, Dept Gastroenterology, Kent and Canterbury Hospital, UK

### References

1. SriRajaskanthan R, Winter M, Muller AF: **Venous thrombosis in inflammatory bowel disease.** *Eur J Gastro Hep* 2005, **17(7)**:697-700.
2. Umit H, Asil T, Celik Y, Tezel A, Dokmeci G, Tuncbilek N, Utku U, Soyulu AR: **Cerebral sinus thrombosis in patients with IBD: A case report.** *World Journal of gastroenterology* 2005, **11(34)**:5404-5407. [PMID:16149158]
3. Tsujikawa T, Urabe M, Bamba H, Andoh A, Sasaki M, Kayama S, Fujiyama Y, Bamba T: **Haemorrhagic cerebral sinus thrombosis associated with ulcerative colitis: a case report of successful treatment by anticoagulant therapy.** *J Gastroenterol Hepatol* 2000:688-692. [PMID: 10921427]
4. Koutroubakis I: **Therapy Insight: vascular complications in patients with inflammatory bowel disease.** *Nature Clinical Practice Gastroenterology & Hepatology* 2005, **2**:266-272. [PMID: 16265230].
5. Danese S, Papa A, Saibeni S, Repici A, Malesci A, Vecchi M: **Inflammation and Coagulation in Inflammatory Bowel Disease: The Clot Thickens.** *The American Journal of Gastroenterology* 2007, **102(1)**:174-186. [PMID: 17100967].
6. Talbot RW, Heppell J, Dozois RR, Beart RW: **Vascular complications of inflammatory bowel disease.** *Mayo Clin Proc* 1986, **61**:140-145. [PMID: 3080643].
7. Younes-Mhenni S, Derex L, Berruyer M, Nighoghossian N, Philippeau F, Salzmann M, Trouillas P: **Large artery stroke in a young patient with Crohn's disease. Role of vitamin B6 deficiency-induced hyperhomocysteinaemia.** *Journal of Neurological Sciences* 2004, **221(1-2)**:113-115. [PMID: 15178225].
8. Mayeux R, Fahn S: **Strokes and ulcerative colitis.** *Neurology* 1978:571-574. [PMID: 565888].
9. Schneiderman JH, Sharpe JA, Sutton DM: **Cerebral and retinal complications of inflammatory bowel disease.** *Ann Neurol* 1979, **5**:331-337. [PMID: 443768].
10. Novotny D, Rubin R, Slezak F, Porter JA: **Arterial thromboembolic complications of inflammatory bowel disease.** *Diseases of the colon and rectum* 1992, **35(2)**:193-196.
11. Webberley MJ, Hart MT, Melkian V: **Thromboembolism in IBD.** *Gut* 1993, **34**:247-251. [PMID: 8432482].
12. Miehsler W, Reinisch W, Valic E, Osterode W, Tillinger W, Feichten-schlager T, Grisak J, Machold K, Scholz S, Vogelsang H, Novacek G: **Is IBD an independent risk factor for thromboembolism.** *Gut* 2004, **53**:542-548. [PMID: 15016749].
13. Koutroubakis I: **Unravelling the mechanisms of thrombosis in inflammatory bowel disease.** *Am J Gastroenterol* 2001, **96**:1325-1327. [PMID: 11374663].

14. Yurekli BPS, Aksoy DY, Aybar M, Egesel T, Gurgey A, Hascelik G, Kirazli S, Haznedaroglu IC, Arslan S: **The search for a common thrombophilic state during the active state of inflammatory bowel disease.** *J Clin Gastroenterol* 2006, **40(9)**:809-813.
15. Danese S, Katz J, Saibeni , Papa A, Gasbarrini A, Vecchi M, Fiocchi C: **Activated platelets are the source of elevated levels of soluble CD40 ligand in the circulation of inflammatory bowel disease patients.** *Gut* 2003, **52**:1435-1441. [PMID: 12970136].
16. Koutroubakis I, Theodoropoulou A, Xidakis C, Sfiridaki A, Notas G, Kolios G, Kouroumalis EA: **Association between enhanced soluble CD40 ligand and prothrombotic state in inflammatory bowel disease.** *Eur J Gastro Hep* 2004, **16**:1147-1152. [PMID: 15489674].
17. Irving PM, Pasi JK, Rampton DS: **Thrombosis and inflammatory bowel disease.** *Clinical Gastroenterology and Hepatology* 2005, **3**:617-628. [PMID: 16206491].
18. Irving PM, Macey MG, Webb , Langmead L, Rampton DS: **Formation of platelet leucocyte aggregates in inflammatory bowel disease.** *Inflammatory bowel disease* 2004, **10(4)**:361-372.
19. Carter MJ, Lobo AJ, Travis SP: **Guidelines for the management of inflammatory bowel disease in adults.** *Gut* 2004, **53(suppl 5)**:v1-v16.
20. Pessin MS, Estol CJ, Lafranchise F, Caplan LR: **Safety of anticoagulation in haemorrhagic infarctions.** *Neurology* 1993, **43**:1298-1303.
21. Novacek G, Haumer M, Schima W, Muller C, Mieshler W, Polterauer P, Vogelsang H: **Aortic mural thrombi in patients with Inflammatory bowel disease.** *Inflammatory bowel disease* 2004, **10(4)**:430-435.

Publish with **BioMed Central** and every scientist can read your work free of charge

*"BioMed Central will be the most significant development for disseminating the results of biomedical research in our lifetime."*

Sir Paul Nurse, Cancer Research UK

Your research papers will be:

- available free of charge to the entire biomedical community
- peer reviewed and published immediately upon acceptance
- cited in PubMed and archived on PubMed Central
- yours — you keep the copyright

Submit your manuscript here:  
[http://www.biomedcentral.com/info/publishing\\_adv.asp](http://www.biomedcentral.com/info/publishing_adv.asp)

